

*Short communication*

## **Surgical correction of recurrent rectal prolapse by colopexy in cats**

*Bibek Chandra Sutradhar\*, Ummay Khaer Fatema Chy, Ankon Das, Debashish Sarker, Thomby Paul, Avi Das and Arifa Akter*

Department of Medicine and Surgery, Chattogram Veterinary and Animal Sciences University, Chattogram 4225, Bangladesh

### **A R T I C L E I N F O**

Article history:

Received: 19/02/2023

Accepted: 10/06/2023

*Keywords: Recurrent rectal prolapse, colopexy, cat*

*\*Corresponding author:*

Cell: +880 1711057533

E-mail: bibeksd@yahoo.com

### **A B S T R A C T**

Colopexy is a surgical procedure to treat recurrent rectal prolapse, in which the colon is attached to the abdominal wall commonly used in dogs and cats. Three surgical techniques were designed to treat rectal prolapse; perianal purse-string suture, colopexy, and rectal resection in our experiment. Purse-string sutures were often unsuccessful unless the condition causing the problem was readily treatable. In colopexy, permanent fibrous adhesion was occurred and recurrent rectal prolapse was maintained. Rectal resection had several postoperative complications, such as stricture formation, incontinence, and dehiscence which were life-threatening. Therefore, colopexy was selected as the final option to correct rectal prolapse, especially in recurrent cases. It was evaluated on four clinical cases of cat suffering from recurrent rectal prolapse admitted in Shahedul Alam Quadary Teaching Veterinary Hospital (SAQTVH), CVASU. Three of them were suffering from constipation, and one had diarrhea for several days with rectal prolapse. Two different colopexy techniques were used to appose the edges of incised colon and abdominal wall. Continuous suture technique was used in two cats and simple interrupted suture technique was used in another two cats. Follow-ups were made weekly on schedule for six months postoperatively, where the cats were totally normal and healthy. Colopexy, using either surgical technique described here, was very much effective in preventing recurrent rectal prolapse.

*To cite this paper: B. C. Sutradhar, U. K. F. Chy, A. Das, D. Sarker, T. Paul, A. Das and A. Akter, 2023. Surgical correction of recurrent rectal prolapse by colopexy in cats. Bangladesh Journal of Veterinary and Animal Sciences, 11(1): 62-66.*

### **1. INTRODUCTION**

Rectal prolapse happens when the rectum becomes stretched and sticks out from the anus. In kittens, it is the most commonly associated with severe endoparasitism, enteritis, and associated tenesmus (Fossum et al., 2013). The initial treatment that is manual reduction with purse string suture, usually directed chances of recurrence are very high, prophylactic colopexy as the modality of choice should be considered (Sherding, 1996) and surgical intervention is required in recurring or long-standing cases (Slatter, 2003). Other conditions that may cause

rectal prolapse include intestinal neoplasia and foreign bodies, dystocia, urolithiasis, constipation, congenital defects, prostatic disease, and rectal polyps (Slatter, 2003). Colopexy, using non incisional suturing between the colon and the abdominal wall where the incisional and scarified colopexy techniques produced a permanent adhesion both clinically and histologically (Popovitch et al., 1994). Therefore, we decided to perform incisional colopexy that may provide a more permanent pexy to give a better long-term clinical result.

## 2. CASE PRESENTATION

Four cats were brought to Shahedul Alam Quadary Teaching Veterinary Hospital (SAQTVH), Chattogram Veterinary and Animal Sciences University (CVASU), all cats were suffering from 1-2 months with intermittent rectal prolapsed (Figure 1A). Prolapsed rectum was reduced and purse string suture was applied three times prior to this procedure. Physical examination revealed that abdominal straining with constipation in 3 cats and other one had diarrhea. Since recurrence of prolapsed rectum was reported 2-3 times after manual repositioning and suturing, incisional colopexy was decided.

### Patient preparation and anaesthesia

Caudal ventral abdominal region was clipped and the surgical site was sterilized with povidone iodine. Gaseous anaesthesia was performed in every case with halothane. The patients were premedicated with xylazine (Xylazine®, Indian Immunologicals Ltd., India) intramuscularly at the dose rate of 1mg/kg body weight. The induction was done with ketamine (Ketalar®, Popular Pharmaceuticals Ltd.,

Bangladesh) intravenously at the dose rate of 5mg/kg body weight. The anaesthesia was maintained with halothane (0.5%-3%). Continuous rate of infusion (CRI) ofentanyl was also added during the whole surgery @ 2 µgm/kg body weight/hour, i/v.

### Surgical technique

The cats were placed on the operation table at dorsal recumbency. An incision was made at the ventral midline and the colon was pulled to return its normal position (Figure 1B). A three cm sero-muscular incision was made along with the anti-mesenteric border of colon and similar incision was made around 2-3cm lateral to the linea-alba through the peritoneum and the underlying muscle of the left abdominal wall (Figure 1C). Then the edges of sero-muscular incisions were apposed to the edges of the incised abdominal wall with absorbable 3-0 catgut with two different suturing techniques. In two cats it was done by simple continuous suture technique and in other two cats simple interrupted suture technique was performed, followed by suture of the abdominal wall (Figure 1D,E). Then the abdomen was closed in routine manner (Figure 1F).

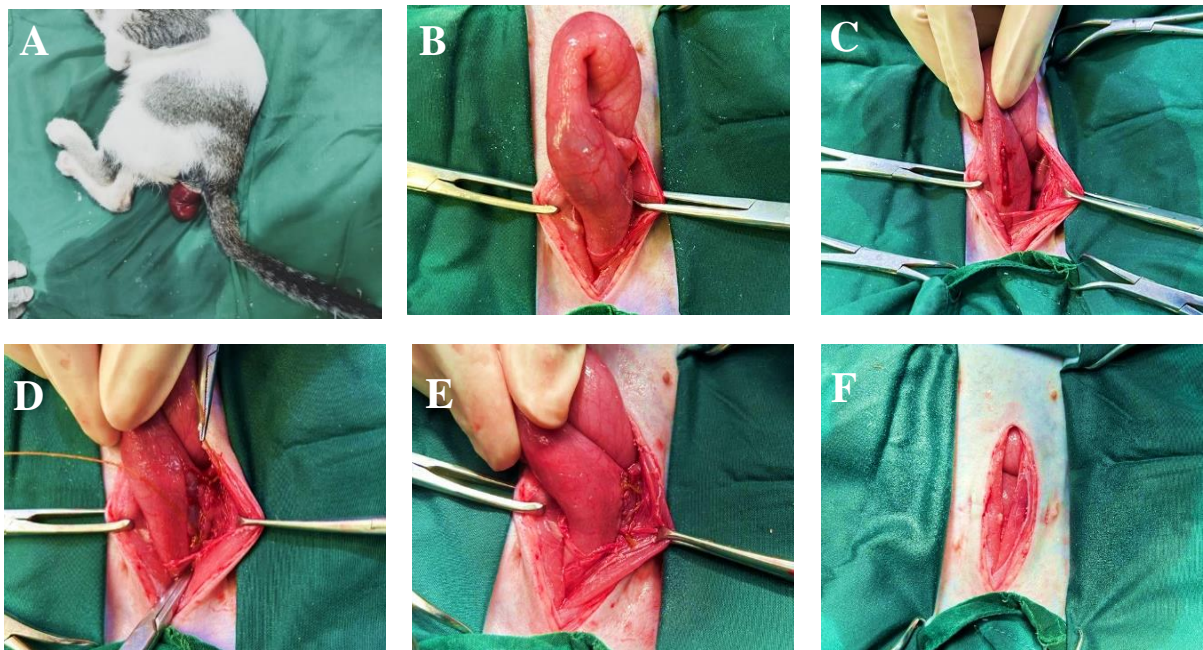


Figure 1: (A) Swelling and redness of the rectum (B) Descending colon was corrected to its normal position (C) Incision at the colon and left abdominal wall (D) Simple continuous suture using to close incisions (E) Colon attached with the abdominal wall. (F) Closing of the abdomen

### Post-operative management

Post operatively, combination of amoxicillin and clavulanic acid was given intramuscularly at the dose rate of 20mg/kg OD for 7 days and analgesic was administered for 3 days. Strict diet (soft food) was advised for another 7 days and then gradually changing the diet to normal food. Additionally, oral administration of laxative was started after 4 days post-operatively and continued for 7 days to allow easy passage of feces and prevent any straining during defecation. Skin suture was removed after 14 days without any complications.

### 3. RESULTS

The anaesthetics recovery was smooth with cuffing reflex in due time and normal heart rate, respiratory rate (Table 1). Non invasive blood pressure (NIBP) and saturation of peripheral oxygen (SpO<sub>2</sub>) were also found normal after anesthesia recovery (Table 1). No postoperative complication was found in every cat. After two weeks of surgery, the cats were completely recovered with the absence of any inflammatory sign. The recurrent rectal prolapse was not seen in the cats after colopexy at six months of follow-up periods (Table 2). Intestinal functions are not adversely affected by this technique.

Table 1. Average heart rate, respiratory rate, non-invasive blood pressure, NIBP, SpO<sub>2</sub> and EtCO<sub>2</sub> (End tidal CO<sub>2</sub>) in 4 cats during maintenance of anesthesia in vital sign monitor

Patient	Heart rate (bpm)	Res. Rate (/min)	NIBP (mmHg)	SpO <sub>2</sub> (%)	EtCO <sub>2</sub> (mmHg)
Cat 1	140	18	130	99	45.2
Cat 2	130	14	120	100	40
Cat 3	135	15	125	100	42
Cat 4	140	20	135	99	42.8

Table 2. Result of colopexy surgery on four clinical cases

Patient no.	Presenting Complaint	Occurrence	Surgical technique	Recurrence
<b>Case 1</b> Five month old female persian	Recurrent rectal prolapse	2 times	Incisional colopexy with simple continuous suture technique	No
<b>Case 2</b> Eight month old male persian	Recurrent rectal prolapse	3times	Incisional colopexy with simple interrupted suture technique	No
<b>Case 3</b> Seven month old male local	Recurrent rectal prolapse	2times	Incisional colopexy with simple interrupted suture technique	No
<b>Case 4</b> Ten month old female mixed	Recurrent rectal prolapse	3times	Incisional colopexy with simple continuous suture technique	No

### 4. DISCUSSION

Incisional colopexy performed in four cats in our study provides a good clinical outcome without any post-operative complications or recurrences which were previously failed to response to multiple attempts of manual reduction and purse string suture in recurrent rectal prolapse. In colopexy, the permanent adhesion by forming sufficient scar tissue between colon and abdominal wall prevents further recurrence of the prolapse (Zhang et al.,

2012). In our study, all cats had constipation and diarrhoea which were considered as the consequence of prolonged tenesmus resulting from different anorectal or urogenital diseases. (Slatter, 2003) and predisposition of the condition includes dyschezia associated with severe typhlitis, colitis, gastrointestinal parasitism (Slatter, 2003; Secchi et al., 2012; Popovitch et al., 1994). The cases included in our present study were Persian (n=2), local (n=1) and mixed (n=1) breed cats with the age

of five months to ten months though no breed predilection has been reported previously but there were increased incidence reported in younger animals similarly in our study (Slatter, 2003). The age range reported by other studies revealed six month to thirteen years in dog and cat (Popovitch et al., 1994; Secchi et al., 2012). According to Popovitch et al. (1994) identification and correction of the primary cause of straining is essential for the treatment of rectal prolapse. In our study, the initial treatment decided for rectal prolapse was reduction and placement of purse string suture but 2 to 3 times recurrence of the rectal prolapse was seen in every case. Rectal amputation and anastomosis is another technique but according to Slatter (2003), the complication includes anorectal stricture, incontinence, dehiscence, leakage and recurrence. Therefore, incisional colopexy was the final choice of technique to correct the recurrent rectal prolapse in our study, which was similarly considered as the safe and effective technique by (Monnet and Smeak, 2020; Popovitch et al., 1994; Fossum et al., 2013). Besides incisional colopexy, laparoscopic assisted colopexy is considered as another equally effective technique by the author (Zhang et al., 2012). According to Monnet and Smeak, 2020, ventral midline approach is the choice which was similar to our study. All patients of our study were received effective surgical anaesthesia followed by smooth recovery from the selected anaesthesia protocol and the intra operative cardiopulmonary parameters were found to be within acceptable ranges. Besides, other researches proposed different anesthesia protocols, which were also effective for the surgical procedure (Fossum et al., 2013; Zhang et al., 2012; Kumar et al., 2012). The selected suture material was absorbable 3-0 catgut and the suture pattern was simple interrupted in two cases and simple continuous in the other two cases. In addition, absorbable polyglycolic acid suture in simple continuous pattern was used (Zhang et al., 2012). Another study (Vikash et al., 2022) used simple interrupted pattern suture with absorbable polyglactin. Non absorbable suture was also used in incisional colopexy without any complication by (Fossum et al., 2013) and (Popovitch et al., 1994). Various post-operative complications were documented by numerous investigations previously those

included infection as the common complication of incisional colopexy (Fossum et al., 2013), adenocarcinoma as a complication after incisional colopexy in a dog (Taylor et al., 2020) as well as urinary incontinence due to excessive suture tension in colon (Monnet and Smeak, 2020). But in our study, no postoperative complications and recurrence of the rectal prolapsed was found. The clinical outcome was satisfactory and incisional colopexy was validate as a suitable technique for rectal prolapse correction in cat.

## 5. CONCLUSION

Incisional colopexy is an effective method for the correction of recurrent rectal prolapse. By this technique, permanent fibrous adhesion was formed with reduction of the colon and rectum and recurrent rectal prolapse was prevented.

## ACKNOWLEDGEMENT

The authors acknowledge the support and cooperation of Upazila Livestock Officer, and Veterinary Surgeon of Upazila Livestock Office and Veterinary Hospital, Savar, Dhaka, Bangladesh during the study.

## REFERENCES

- Fossum, T. W., Dewey, C. W., Horn, C. V., Johnson, A. L., MacPhail, C. M., Radlinsky, M. A.G., Schulz, K. S. and Willard, M. D. 2013. *Small Animal Surgery*. 4th ed. Philadelphia: Elsevier Mosby, St. Louis Missouri, 536-537.
- Kumar, V., Ahmad, R.A. and Amarpal., 2012. Colopexy as a treatment for recurrent rectal prolapse in a dog. *Indian Journal of Canine Practice*, 4(2): 138–140.
- Monnet, E. and Smeak, D. D. 2020. *Gastrointestinal surgical techniques in small animals*, John Wiley & Sons. 1st ed. 231-233.
- Popovitch, C. A., Holt, D. and Bright, R. 1994. Colopexy as a treatment for rectal prolapse in dogs and cats: a retrospective study of 14 cases. *Veterinary Surgery*, 23(2):115-118.
- Secchi, P., Filho, H. C. K., ScusselFeranti, J. P., de Oliveira, M. T., Gottlieb, J., Guedes, R. L., Colomé, L. M. and Brun, M. V. 2012. Laparoscopic-assisted incisional colopexy by two portals access in a domestic cat with recurrent rectal prolapse. *Journal of Feline Medicine and Surgery*, 14(2): 169-170.

- Slatter, D., 2003. Textbook of Small Animal Surgery. 3rd ed. Philadelphia: Saunders, USA, 686-689.
- Vikash, S. H., Purohit S. and Pandey R. P. 2022. Colopexy for management of recurrent rectal prolapse in a dog. Indian Journal of Veterinary Surgery, 43(1): 80–80.
- Zhang, S., Zhang, J., Zhang, N., Shi, J. and Wang, H. 2012. Comparison of laparoscopic assisted and open colopexy in dogs. Journal of Veterinary Research, 56(3): 415-417.