

*Case Report***Pathological investigation of a unilateral spermatocytic seminoma in a dog**Zinnurine, S.<sup>1</sup>, Das, B.C.<sup>2</sup>, Kamal, T.<sup>1</sup> and Siddiki A.M.A.M.Z.\*<sup>1</sup> Department of Pathology and Parasitology<sup>2</sup> Department of Medicine and Surgery, Chattogram Veterinary and Animal Sciences University, Khushi-4225, Chattogram, Bangladesh.**ARTICLE INFO***Article history :*

Received : 30/04/2019

Accepted : 19/09/2019

*Keywords :*

Dog, Seminoma, Histopathology

*\* Corresponding Author :*

Cell: +8801717718884

E-Mail: zsiddiki@gmail.com

**ABSTRACT**

A 10 years old male dog with unilateral testicular enlargement was diagnosed with spermatocytic seminoma. Typical neoplastic cells were found by histopathological investigation followed by physical and haematological examination. The case was treated by surgical intervention and found no recurrence.

*To cite this paper :* Zinnurine, S., Das, B.C., Kamal, T. and Siddiki A.M.A.M.Z. 2019. Pathological investigation of a unilateral spermatocytic seminoma in a dog. *Bangladesh Journal of Veterinary and Animal Sciences*, 7 (1): 79-81

**1. INTRODUCTION**

Testicular tumors are the most common neoplasm of the genital system in male dogs and are the third most common type of canine tumor after skin and fibrous tissue tumors (Nødtvedt *et al.*, 2011). Testicular tumors are known to originate from either germ cells or sex cord stromal element while mixed type also may occur. Seminoma is a type of tumor originated from testicular germ cell which is more common in dogs than any other species (McLachlan and Kennedy, 2002). A longer life span of dogs (usually over 10 years) and less frequent castration in comparison with other species significantly affect the high incidence of the tumors in this species and mostly occur unilaterally, though a bilateral location is not unusual (Kennedy *et al.*, 1998). The seminoma are usually unilateral and more frequently found in the right testicle and may coexist with other types of sertoli cell and Leydig cell tumor. Based on the histological findings, seminomas are subdivided into intratubular and diffuse types. Canine

seminomas are mostly benign; however, it does metastasize less frequently (Foster *et al.* 2007). Seminoma and Sertoli cell tumors are more common in cryptorchid testes than in scrotal testes (Reif *et al.*, 1979; Nødtvedt *et al.*, 2011). The aim of this report is to describe histopathological findings of a unilateral diffuse seminoma case observed in a Golden Retriever dog.

**2. MATERIALS AND METHODS****Case Presentation**

A 10-year-old male Golden Retriever dog weighing 30 kg had a history of enlarged testes over a 6 month period. During physical examination a considerable disparity in the size of testes was identified. Palpation demonstrated enlargement of the left testis and the right one was normal (Figure 1) and there was no pain sensation. The surface of both testicles was smooth, without any signs of nodular hyperplasia. The examination also

identified no adhesions or fluid within the scrotum. However the enlarged testes had a hard consistency as felt during palpation. There was no sign of gynaecomastia. Blood test showed no abnormal results.

#### **Surgical removal of the testes:**

Following premedication with intravenous xylazine (1.1mg/kg body weight), mixture of ketamine (10mg/kg bw) and xylazine (1mg/kg bw) was used for general anesthesia. Both testicles were removed by routine surgical procedure (Masand *et. al.*, 2013; Figure 2).

#### **Gross and histopathological examination**

Following detailed gross examination, the specimen pieces were fixed in 10% neutral buffered formalin. Later the tissue were routinely processed and embedded in paraffin wax and cut into 1mm thick sections. Cut sections were stained with haematoxylin and eosin (HE) for subsequent histopathological examination.

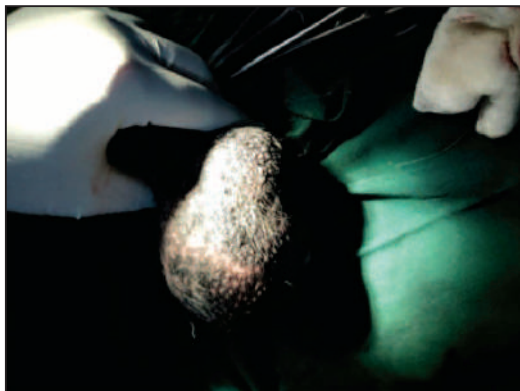### **3. RESULTS AND DISCUSSION**

In gross examination, the left testis was found enlarged about 3-4 times higher than right one. The excised

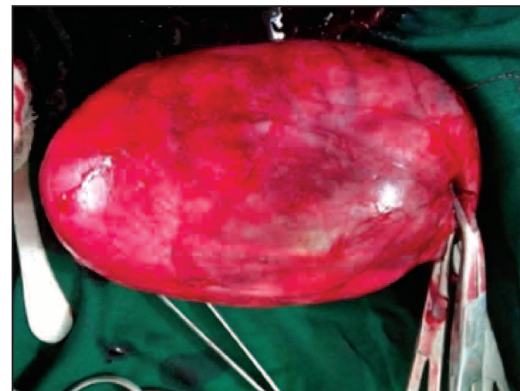testis was measured approximately 13×10×8cm and outer surface was multilobulated. The cut surface of testis was hard to cut and constituted less than 5% normal testicle parenchyma. The vast majority constituted an abundant light greyish parenchyma of the tumor tissue covering approximately 90% of the testis surface. The cut surface had multiple necrotic foci and haemorrhage (Figure 3).

The microscopic examination of the sections stained with H&E identified a dominant tumor proliferation of the disseminated seminoma type neoplastic cells. Testicular tissue revealing a malignant neoplasm composed of small to medium sized round cells with hyperchromatic nuclei and highly eosinophilic cytoplasm arranged in ill-defined lobules infiltrating the surrounding stroma (Figure 4). High mitotic figures were also evident (Figure 4).

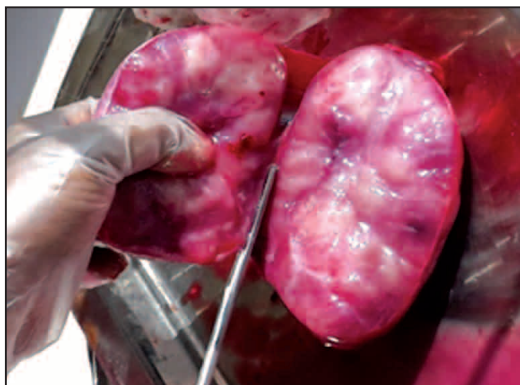Based on the gross and histopathological observation, the tumor was characterized as seminoma, which shows the rapid growth rate, high proliferative capacity.



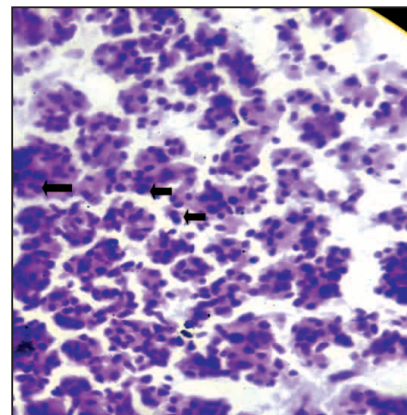
**Figure 1.** Enlarged testicular mass



**Figure 2.** Surgical removal of the enlarged testicular mass



**Figure 3.** Hemisected orchioectomy specimen showing nodules with a glistening cut surface and cystic spaces separated by fibrous sept



**Figure 4.** Round to ovoid nucleus with scant cytoplasm, arrows in this picture indicate mitotic figures

Scrotal enlargement in dog may occur due to both inflammatory and non-inflammatory causes. In the present case, the clinical pathology tests including blood profile and fine needle aspiration cytology (FNAC) indicated it a non-inflammatory cause. External examination revealed that dermis was quite edematous, indicating that the enlargement in scrotum was possibly the result of the existing tumour. Seminomas are classified as benign or malignant according to pleomorphic changes, mitotic activity and metastatic characteristics (Grieco *et al.*, 2007). Diffusely spread anaplastic cells were evident with pleomorphism, vacuolar nuclei and slightly basophilic cytoplasm indicating malignancy (Ibrahim *et al.*, 2013). In addition, pleomorphic changes were evident along with moderate mitotic activity.

## 5. CONCLUSIONS

Based on the clinical and histopathological findings, it can be concluded that it was a case of unilateral diffuse seminoma. Further immunohistochemical diagnosis and molecular characterization can differentiate among various kinds of testicular tumors in canines.

## 6. REFERENCES

Akin, I., Avci, H., Gulaydin, A., Belge, A., and Yaygingul, R. 2013. Bilateral Malignant Seminoma in Two Dogs. Kafkas Universitesi Veteriner Fakultesi Dergisi. 19 (Suppl-A): A233-A236.

Foster, R.A., Ladds, P.W. Male genital system. 2007. Jubb, Kennedy, and Palmer's Pathology of domestic animals. Edited by Grant Maxie M. Elsevier Saunders, Philadelphia. 565-619pp.

Grieco, V., Riccardi, E., Greppi, G. F., Teruzzi, F., Iermano, V., and Finazzi, M. 2008. Canine testicular tumours: a study on 232 dogs. J Comp Path. 138:86-89.

Kennedy, P.C., Cullen, J.M., Edwards, J.F., Gold Schmidt, M.H., Larsen, S., Munson, L., and Nielsen, S. 1998. Histological Classification of Tumors of Domestic Animals. In: Histological classifications of tumors of the genital system of domestic animals (Second series). Washington DC: Armed forces institute of pathology in corporation with World health organization International, 17-18pp.

MacLachlan, N. J., Kennedy, P.C. 2002. Tumors of the genital systems. In: Tumors in domestic animals, (4<sup>th</sup> edition). California: Iowa State Press, 547-573pp.

Masand, A., Kumar, N., and Patial, V. 2013. Unilateral diffuse spermatocytic seminoma in a dog. Veterinary Research International. 1 (2): 46-48

Nødtvedt, A., Gamlem, H., Gunnes, G., Grotmol, T., Inderbø, A., and Moe, L. 2011. Breed differences in the proportional morbidity of testicular tumors and distribution of histopathologic types in a population-based canine cancer registry. Vet Comp Oncol., 9:45-54.

Reif, J.S., Maguire, T. G., Kennedy, R.M. and Brodey, R.S. 1979. A cohort study of canine testicular neoplasia. J. Am. Vet. Med. Assoc., 175: 719-723.